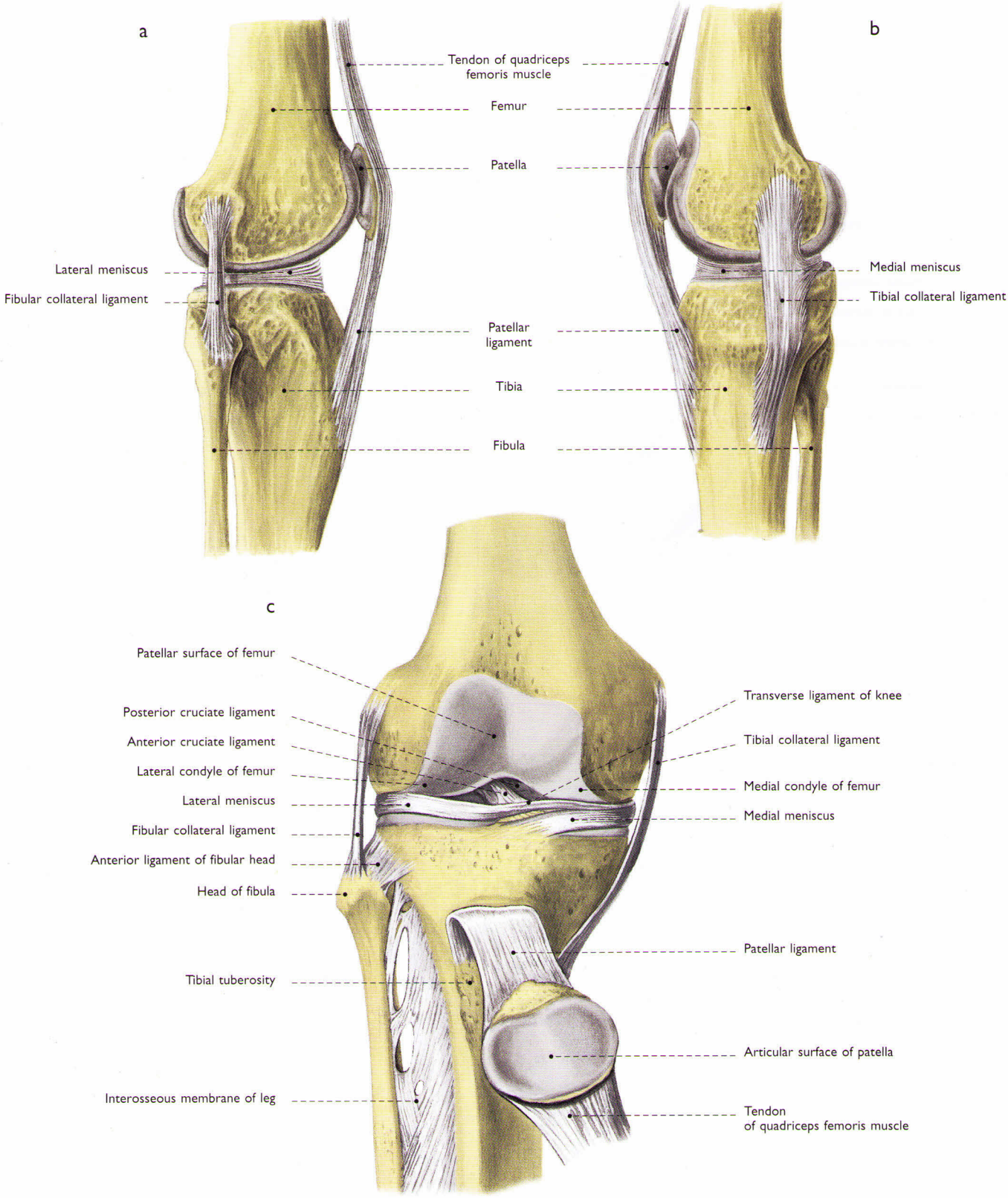

95 Right knee joint

The capsule was removed.

a Lateral aspect (50%)
b Medial aspect (50%)
c The patella was turned downwards (70%). Ventral aspect